Neuroscience Midterm

9th Batch - 2017-2018

60/60 MCQS

1- A 72-year-old woman trips and falls down the stairs. She does not lose consciousness. She develops a headache and confusion 30 hours later and is taken to the emergency department. On physical examination, she is conscious and has a scalp contusion on the occiput. What is the most likely location of an intracranial hemorrhage in this patient?

A. Basal ganglia
B. Epidural
C. Pontine
D. Subarachnoid
E. Subdural

Ans: E

2- A 54-year-old man with 3 months history of headaches in brought to the emergency department following a generalized tonic-clonic seizure. On physical examination, he has weakness on the right side. An MRI of his brain shows a large, irregular, 6 cm mass in the left cerebral hemisphere that extends across the corpus callosum. A stereotaxic biopsy of the mass is done and histological findings are shown in the figure. Which of the following neoplasms does he most likely to have?

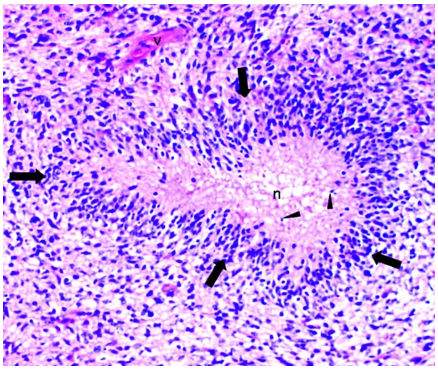

A. Meningioma
B. Medulloblastoma
C. Hemangioblastoma
D. Glioblastoma multiforme
E. Diffuse large B-cell lymphoma

Ans: D

3- A 65-year-old woman who fell to the ground and hit her head, is taken to the emergency department. Physical examination is unremarkable. CT scan of the head shows no hemorrhage or fracture, but there is a 5cm mass beneath dura that compresses the underlying right parietal lobe. The mass is surgically removed. Histologic sections from the mass would most likely reveal:

A. Antoni A areas and Antoni B areas with Verocay bodies
B. Whorls of meningo epithelial cells and scattered psammoma bodies
C. Endothelial proliferation and nuclear pseudopalisading around necrotic area
D. Fried-egg appearance of tumor cells with scattered calcification
E. Sheets of anaplastic small blue cells with Homer-Wright rosettes

Ans: B

4-The parasympathetic ganglion of the glossopharyngeal nerve is?

A.Otic ganglion
B.Pterygoid ganglion
C.Submandibular ganglion
D.Sublingual ganglion

Ans: A

5-In which of the following points, K+ conductance exceeds the Na+ conductance during a normal action potential?

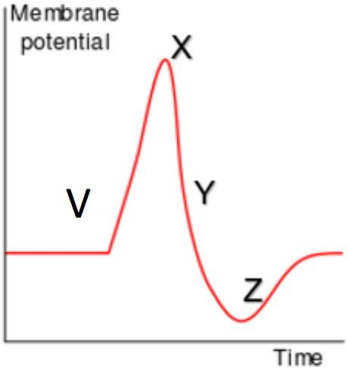

A. X,Y,Z
B. X,Z
C. V,X,Y
D. V,Z

Answer: D

6-A patient has some burns and his extracellular K+ concentration dropped from 4 to 2.5, what will happen to the resting membrane potential and the K+ Nernst Potential (EqK)?

A. More negative, More negative
B. More Positive, More negative
C. More positive, More positive
D. More Negative, More positive
E. None of the above

Ans: A

7-Which of the following is the mechanism of action of opioid on postsynaptic neuron?

A. K+ channel activation/ potassium efflux
B. Opens Ca 2+ channels
C. Opens Na+ channels
D. Opens glutamate channels

Ans: A

8-Which of the following drugs is used in detoxification therapy for heroin addicts?

A. Methadone
B. Meperidine
C. Naloxone
D. Naltrexone
E. Morphine

Ans: C

9-Why is epinephrine administered with local anesthetics?

A. Prolongs duration of action
B. increases its metabolism
C. increases the efficacy of the drug
D. Reduces the side effects of the anesthetic

Ans: A

10-Which of the following glial cells are involved in maintaining the blood brain barrier?

A. Neupril
B. Astrocytes
C. Schwann cells
D. Oligodendroglia
E. Microglia

Ans: B

11- A 15 year old girl was brought to neurological clinic as her mother noticed a weakness on the right side of her face. It was noticed that her mouth was pulled to the left side. On neurological examination there was definite weakness of the facial muscles on the right side. The skin sensation on the face was normal. Her right eye was deviated medially and she was unable abduct her right eye. She has spastic type of paralysis involving his left arm and leg. Where is the site of lesion in this case?

A. Left pons
B. Right pons
C. Right medulla
D. Left medulla
E. Midbrain

Ans: B

12-A 66-year-old man receiving hemodialysis for chronic renal failure has noted increasing loss of sensation in his legs for the past 4 years. On physical examination, there is symmetrically decreased sensation over both lower extremities. He has no decrease in strength or abnormality of gait. Which of the following findings confirms the diagnosis in the case?

A. Random blood glucose level 220 mg/dL
B. Reduced serum levels of vitamin B12
C. Increased serum levels of lead
D. Positive culture for campylobacter jejuni
E. Congo red positive material in the blood vessels of extremities

Ans: A

13- A 68-year-old obese woman (BMI = 34 kg/m2) suffers a stroke and expires. Histologic examination of the brain at autopsy reveals extensive arteriolar lipohyalinosis and numerous Charcot-Bouchard aneurysms. Which of the following best accounts for the pathogenesis of these autopsy findings?

A. Atherosclerosis
B. Autoimmunity
C. Diabetes
D. Hypertension

E. Vasculitis

Ans: D

14-A 30-year-old woman presents to the emergency room complaining that she has the "worst headache" of her life. Her temperature is 37°C (98.6°F), blood pressure 135/85 mm Hg, and pulse 90 per minute. The patient shows no evidence of muscle weakness or ataxia. Imaging studies reveal subarachnoid hemorrhage, and an angiogram shows a saccular aneurysm. Which of the following best describes the pathogenesis of aneurysm formation in this patient?

A. Atherosclerosis
B. Bacterial infection
C. Congenital weakness
D. Diabetes Mellitus
E. Systemic hypertension

Ans: C

15- A 60-year-old man is brought to the emergency room in a coma. Physical examination reveals an emaciated man with a distended abdomen, jaundice, ascites, and a slightly enlarged liver and spleen. Laboratory studies show elevated levels of blood ammonia. A liver biopsy demonstrates cirrhosis. Histologic examination of brain tissue from this patient would most likely show prominent changes in the nuclei of which of the following cell types?

A. Astrocytes
B. Ependymal lining cells
C. Microglia
D. Neurons
E. Oligodendroglia

Ans: A

16-A patient presents after having a motor vehicle accident. He initially lost consciousness and then came about and complained of severe headache and blurry vision on the way to the hospital. He then became comatose. X-ray imaging showed that he had a fracture at the temporoparietal bone and 6 hours after craniotomy he died. Which of the following vessels was most likely to be injured in this case?

A. Middle cerebral artery
B. Bridging veins
C. Anterior cerebral artery
D. Posterior cerebral artery
E. Middle meningeal artery

Ans: E

17-A patient whose glasgow scale was 12 and he started having sudden severe headache. Where would you have the hemorrhage?

A. Subarachnoid hemorrhage
B. Subdural Hemorrhage
C. Epidural Hemorrhage
D. Intraparenchymal Hemorrhage
E. Pontine hemorrhage

Ans: A

18-A patient came to the link complaining of sensory loss all the way up to the thighs. Upon examination, there was a muscle power of ⅘ on both limbs but without loss of sensory sensation on both limbs. This started in the distal lower limbs but it has now progressed all the way to the lower thighs. What sort of neuropathy is suspected in this patient?

A. Multiple sclerosis
B. Acute Inflammatory demyelinating Polyneuropathy
C. Chronic Inflammatory demyelinating polyneuropathy
D. Amyotrophic lateral sclerosis (ALS)
E. diabetes

Ans: B

19-What is the best verbal glasgow score given to a person that says incomprehensible words?

A. 0
B. 1
C. 2

D. 3
E. 4

Ans: C

20- A 3 year old girl was presented with ataxia. After an MRI it was found that there was a midline tumor that caused her to lose her balance. Which of the following tumors did the girl have?

A. Medulloblastoma
B. Meningioma
C. Ependymoma
D. Oligodendroglioma
E. Glioblastoma

Ans: A

21- A 73-year-old man is undergoing radical prostatectomy for prostatic adenocarcinoma. During this procedure the anesthesiologist reports a drop in blood pressure with hypotension that persists for 30 minutes despite intervention with pressor agents. As a consequence, there was damage to the purkinje cells followed by which of the following cell types?

A. Astrocytes surrounding the neurons
B. Pontine nuclei in the pons
C. Pyramidal neurons in the Ca-1 region of the hippocampus
D. Microglial cells

Ans: C

22- What is the first drug line that is given during a status epilepticus?

A. Phenytoin
B. Lorazepam
C. Topiramate
D. Clobazam

Ans: B

23- Which of the following drugs can be used in pregnant women for epilepsy?

A. Clobazam
B. Topiramate
C. Phenytoin
D. Ethosuximide
E. Felbamate

Ans: B

24- A 63 year old man noticed that he was not able to frown on the left side of his face nor he was able to whistle. Which of the following structures would be damaged in this case?

A. Cingulate gyrus
B. Facial nerve
C. Prefrontal area
D. Premotor area
E. Supplementary area

Ans: B

25- Which of the following anesthetics is a parenteral anesthetic with rapid induction?

A. Lidocaine
B. Thiopental
C. Procaine
D. Prilocaine
E. Halothane

Ans: B

26- What hemorrhage looks like a crescent in the CT scan?

A. Subarachnoid hemorrhage
B. Subdural Hemorrhage
C. Epidural Hemorrhage
D. Intraparenchymal Hemorrhage
E. Pontine hemorrhage

Ans: B

27- A patient had degeneration of substantia nigra which will lead to tremors. What structure should be inhibited to ensure smooth movement?

A. Putamen
B. Caudate
C. Globus pallidus
D. Substantia nigra
E. Subthalamus

Ans: C

28- Which of the following structures point to the cerebellopontine cistern?

A. A
B. B
C. C
D. D
E. E

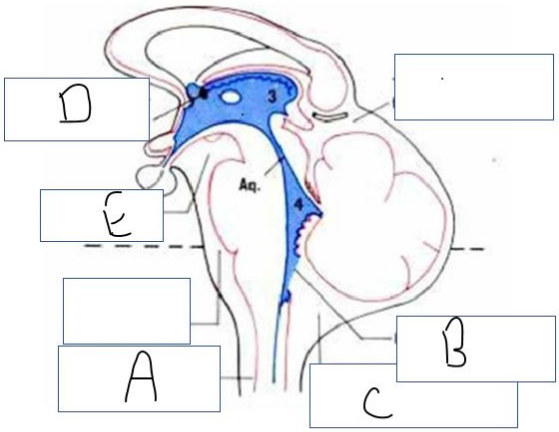

Ans: C

29- A patient presented with an increased ICP, unilateral dilated pupil and abducted eye. Which of the following structures is most likely to be herniated?

A. Cingulate gyrus
B. Uncus
C. Tonsils
D. Thalamus
E. Medulla

Ans: B

30- A patient was brought to the emergency room after being involved in a fight. There was a stab wound on his upper back that caused a hemisection of the respective spinal cord level, which of the following could happen?

A. Complete loss of sensation ipsilaterally
B. Loss of pain and temperature ipsilaterally
C. quadriplegia
D. Loss of all sensation bilaterally
E. Loss of 2 touch and vibration contralaterally

Ans: A

31- A patient is presented with chronic back pain for two month and is having problem with sleeping. Which of the following is responsible about his inability to have proper sleep?

A. Periaqueductal gray matter communicates with the raphe nucleus before going to the inhibitory interneurons in the dorsal horn
B. Periaqueductal gray matter communicates with the inhibitory interneurons directly
C. Reticular formation goes to the thalamus and then to the cortex
D. Signals beings sent to the pontine nuclei and then to the cerebellum

Ans: A

32- When a patient was told to perform the finger to nose test he was not able do it properly. He always missed the nose showing either an over exaggerated response or an under exaggerated response. Which of the following structures would be damaged in this case?

A. Frontal cortex
B. Occipital lobe
C. Thalamus
D. Cerebellum
E. Vestibular tract

Ans: D

A 28 year old guy had a hyperextension injury, after 2 weeks he had loss of pain and temperature and hyperreflexia in biceps and triceps reflex in the bilateral upper limb, (lower limb is not affected), two touch discrimination, vibration where intact in both upper and lower limb. (This scenario belongs to Q. 33&34)

33) Which undamaged tract is responsible for intact 2-touch discrimination and vibration in this patient?

A. Fasciculus gracilis
B. Lateral spinothalamic
C. Medial spinocerebellar tract
D. Medial spinothalamic tract

Ans: A

34) What is the diagnosis?

A. Central cord compression
B. Anterior cord injury
C. Right hemisection
D. Left hemisection
E. Complete transection of the spinal cord

Ans: A

35- A patient presented with contralateral hemiplegia and loss of pain and temperature sensation, dysphagia, and ipsilateral loss of pain and temperature on the right side of the face. Which artery supplies the area responsible for the damage?

A. Anterior inferior cerebellar artery
B. Right Posterior inferior cerebellar artery
C. Left Posterior inferior cerebellar artery
D. Middle cerebral artery
E. Paramedian branches of the basilar artery

Ans: B

36- A 45 year old man was having a pain for the past two month. He was not able to have a good sleep the last two month so he resorted to hypnotic drugs. Which of the following is responsible for not allowing the old man to have a good sleep?

A. Activation of the reticular formation
B. Activation of PAG
C. Cingulate gyrus
D. Inhibition of reticular formation

Ans: A

37- A patient came to the clinic complaining of problems swallowing. He was then referred to the neurologist which performed examination and confirmed that the patient had dysphagia, dysarthria, and loss of pain and temperature sensation on the left side of his face. Which of the following tracts is responsible about transmitting the sensation for the face?

A. Spinocerebellar tract
B. Internal Arcuate fibers
C. Lateral corticospinal tract
D. Anterior corticospinal tract
E. trigeminal lemniscus

Ans: E

38- A 35 year old woman had a car accident and was taken to the hospital. During the physical examination the noticed that she was not able to shrug her shoulder and she was having difficulty turning her head. Which of the following nerves is damaged in this case?

A. XII
B. XI
C. IX
D. X
E. V

Ans: B

39- When are the delta waves seen in EEG?

A. Seen normally in adults who are awake
B. Seen in adults with brain disorders
C. Children in deep sleep
D. Seen in adults whose eyes and close and the mind is wandering
E. seen in adults when they are focusing

Ans: B

40- Which waves seen in EEG are the most desynchronized?

A. Alpha waves
B. Beta Waves
C. Theta Waves
D. Delta waves

Ans: B

41- A picture of midbrain at the superior colliculus level. A red circle placed on the red nucleus. Damage to this structure will lead to which of the following?

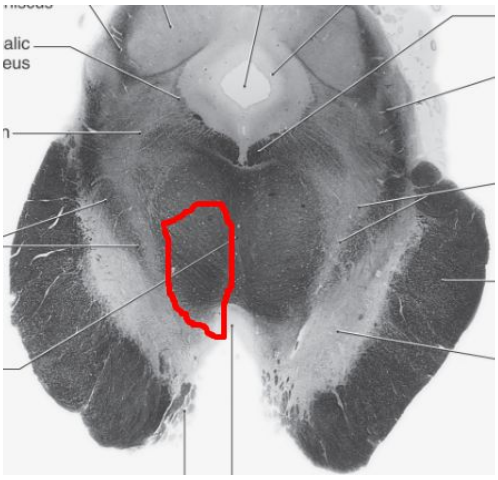

A. Tremor
B. Contralateral paralysis
C. Partial Blindness
D. Bilateral loss of accommodation

Ans: A
(The red circle was pointing to the red nucleus)

42- Which of the following represents the timing of one complete sleep cycle?

A. 30 min
B. 40 min
C. 60 min
D. 90 min
E. 120 min

Ans: D

43- A 68-year-old obese woman (BMI = 34 kg/m2) suffers a stroke and expires. Histologic examination of the brain at autopsy reveals extensive arteriolar lipohyalinosis and numerous Charcot-Bouchard aneurysms. Which of the following best accounts for the pathogenesis of these autopsy findings?

A. Atherosclerosis
B. Autoimmunity
C. Diabetes
D. Hypertension
E. Vasculitis

Ans: D

44- Where does the tracts that transmit the vibration of the index finger cross?

A. In the rostral medulla
B. In the upper cervical cord
C. upper pons
D. midbrain
E. thalamus

Ans: A

45- A hypertensive patient came with a sudden onset of left distal hemiparesis presented in the clinic. A CT scan was normal and thus a MRA was performed which of the following arteries is most likely damaged in the patient?

A. Anterior cerebral artery
B. Basilar artery
C. Middle meningeal artery
D. Cerebellar arteries
E. Middle cerebral artery

Ans: E

46- A virus infected the brain tissue of a 30 year old man and it continued to grow causing tissue damage, which of the following is ultimately responsible for controlling the viral infection in the brain:

A. Antibodies against the viruses
B. CD8+ T cell which kill the targeted cell
C. Antibody mediated cytotoxicity of infected organs.
D. Honeycomb astrocytes enlarge
E. Microglia engulf the infected cells

Ans: B

47- Where are the neurons of the efferent limb of myotatic reflex present?

A. Anterior grey horn cells
B. Interneurons
C. Gamma motor neurons
D. Group Ia afferents

Ans: A

48- A woman presented with rigidity in her lower limb and brisk reflexes upon testing. What type of lesion is seen here?

A. LMN lesions
B. UMN lesion
C. No lesion occurred
D. Hemisection of the spinal cord

Ans: B

49- Which of the following is a monosynaptic reflex?

A.Withdrawal reflex
B. Postural reflex
C. corneal reflex
D. Cross extensor reflex
E. Achilles tendon reflex

Ans: E

50- A patient presented with increased fatigueness throughout the day and the confirmation was made by the doctor as myasthenia gravis. What is the mechanism behind myasthenia gravis?

A. Antibodies against the Ach receptors causing their destruction preventing Ach from binding to it.
B. It causes reduced release of Ca2+ from the presynaptic neuron
C. Antibodies against Ach receptors which resulted in reduced release of Ach from the presynaptic neuron
D. increased activation of the Ach receptors on the postsynaptic neuron.

Ans: A

51- Which of the following can be used as a differentiating factor between ependymoma and demyelinating on an MRI?

A. Expansion of the spinal cord
B. Give gloidnium and get an enhanced image
C. Cord compression

Ans: A

52- A patient was taken to the hospital after a car accident. MRI showed an epidural hemorrhage. Between which two layers is the epidural hemorrhage contained?

A. Between the dura mater and the skull
B. Between the 2 layers of the dura mater
C. Between the pia mater and the parenchyma
D. in the subarachnoid space
E. inside the white matter

Ans: A

53- A patient presented with cardiac failure and he was developing pulmonary edema. Which of the following opioids can be given to save him?

A. Meperidine
B. Dextromethorphan
C. Morphine
D. Codeine
E. Tramadol

Ans: C

54- A patient had an MRI to his spine and it should dilation. The patient did not have any preceding trauma that might have caused it. Which of the following might be the cause?

A. Oligodendroglioma
B. Astrocytoma
C. Medulloblastoma
D. Ependymoma
E. Metastatic tumor

Ans: D

55. A patient presented with worsening vision with time. The doctor performed a CT scan which showed a mass in the parietal lobe. The lesion in the parietal lobe would result in what sort of visual field defect in the patient?

A. Right homonymous hemianopsia
B. Left Homonymous hemianopsia
C. left quadrantanopia
D. Right quadrantanopia

Ans: D

56- A patient was having an ascending weakness in his lower limbs, which happened to be a demyelinating disorder. Which of the following will be seen in this patient if a lumbar puncture was taken?

A. Albuminocytologic dissociation
B. Bacteria in the CSF
C. Increased amount of glucose
D. Decreased protein levels

Ans: A

57- Which of the following drugs is used as an antagonist to benzodiazepines?

A. Flumazenil
B. Bisporone
C. Tramadol
D. Diazepam

Ans: A

58- Which structure is found in the falx cerebri?

A. Superior sagittal sinus
B. Transverse sinus
C. Straight sinus
D. Sigmoid sinus
E. Occipital sinus

Ans: A

59- If this structure was damaged which of the following will occur?

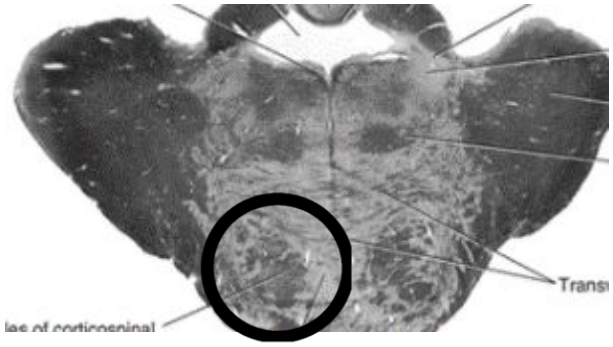

A. Contralateral loss of pain and temperature
B. Contralateral loss of proprioception, vibration.
C. Ipsilateral hemiplegia
D. Contralateral Hemiplegia
E. Ataxia

Ans: D

60- Which of the following would be expected to be lost in a patient with a demyelinating neuropathy?

A. Reflexes

Ans : A

"What was delivered to us from the old generations and what was read in the ancient records of Alfaisal were not enough to elaborate on how different this block was. Embrace yourselves for this block is the first of its kind. I am seeing two types of people after this exam, those who pulled all-nighters and achieved what they wanted and those who wasted their time during the block. I guess you know what happened to the latter. It's your choice to decide which one to become (btw it's extremes in this exam, you either pass with flying colors or you fail miserably) Our prayers as usual for your everlasting success and don't forget us in your prayers."

- The great JJ and Biscuit -

Prepared by Exam Committee of the 9th batch